

Activation of Distinct Motor Cortex Regions During Ipsilateral and Contralateral Finger Movements

STEVEN C. CRAMER,^{1,2,3} SETH P. FINKLESTEIN,¹ JUDITH D. SCHAECHTER,⁴ GEORGE BUSH,^{2,3} AND BRUCE R. ROSEN²

¹Department of Neurology, Massachusetts General Hospital, Harvard Medical School, Boston 02114; ²The MGH-NMR Center, Department of Radiology, Massachusetts General Hospital, Harvard Medical School, Charlestown 02129; ³The Clinical Investigator Training Program, Harvard-MIT Division of Health Sciences and Technology and Beth Israel-Deaconess Medical Center in collaboration with Pfizer, Inc., Boston 02114; and ⁴Department of Physical Therapy, Bouve College of Pharmacy and Health Sciences, Northeastern University, Boston, Massachusetts 02115

Cramer, Steven C., Seth P. Finklestein, Judith D. Schaechter, George Bush, and Bruce R. Rosen. Activation of distinct motor cortex regions during ipsilateral and contralateral finger movements. *J. Neurophysiol.* 81: 383–387, 1999. Previous studies have shown that unilateral finger movements are normally accompanied by a small activation in ipsilateral motor cortex. The magnitude of this activation has been shown to be altered in a number of conditions, particularly in association with stroke recovery. The site of this activation, however, has received limited attention. To address this question, functional magnetic resonance imaging (fMRI) was used to study precentral gyrus activation in six control and three stroke patients during right index finger tapping, then during left index finger tapping. In each hemisphere, the most significantly activated site ($P < 0.001$ required) was identified during ipsilateral and during contralateral finger tapping. In the motor cortex of each hemisphere, the site activated during use of the ipsilateral hand differed from that found during use of the contralateral hand. Among the 11 control hemispheres showing significant activation during both motor tasks, the site for ipsilateral hand representation (relative to contralateral hand site in the same hemisphere) was significantly shifted ventrally in all 11 hemispheres (mean, 11 mm), laterally in 10/11 hemispheres (mean, 12 mm), and anteriorly in 8/11 hemispheres (mean, 10 mm). In 6 of 11 hemispheres, tapping of the contralateral finger simultaneously activated both the ipsilateral and the contralateral finger sites, suggesting bilateral motor control by the ipsilateral finger site. The sites activated during ipsilateral and contralateral hand movement showed similar differences in the unaffected hemisphere of stroke patients. The region of motor cortex activated during ipsilateral hand movements is spatially distinct from that identified during contralateral hand movements.

INTRODUCTION

In normal human subjects performing unilateral finger movements, a variety of methods (Hoshiyama et al. 1997; Kim et al. 1993; Maki et al. 1996; Shibasaki and Kato 1975) has demonstrated increased activity in both ipsilateral and contralateral primary motor cortex before movement (Hoshiyama et al. 1997; Shibasaki and Kato 1975). Ipsilateral motor activity, furthermore, has been shown to be increased in young children (Muller et al. 1997), in the performance of

complex motor tasks (Rao et al. 1993; Salmelin et al. 1995), in the generation of increased levels of force (Dettmers et al. 1995), in schizophrenics (Mattay et al. 1997), and in stroke patients using the recovered hand (Cao et al. 1998; Chollet et al. 1991; Cramer et al. 1997; Weiller et al. 1993).

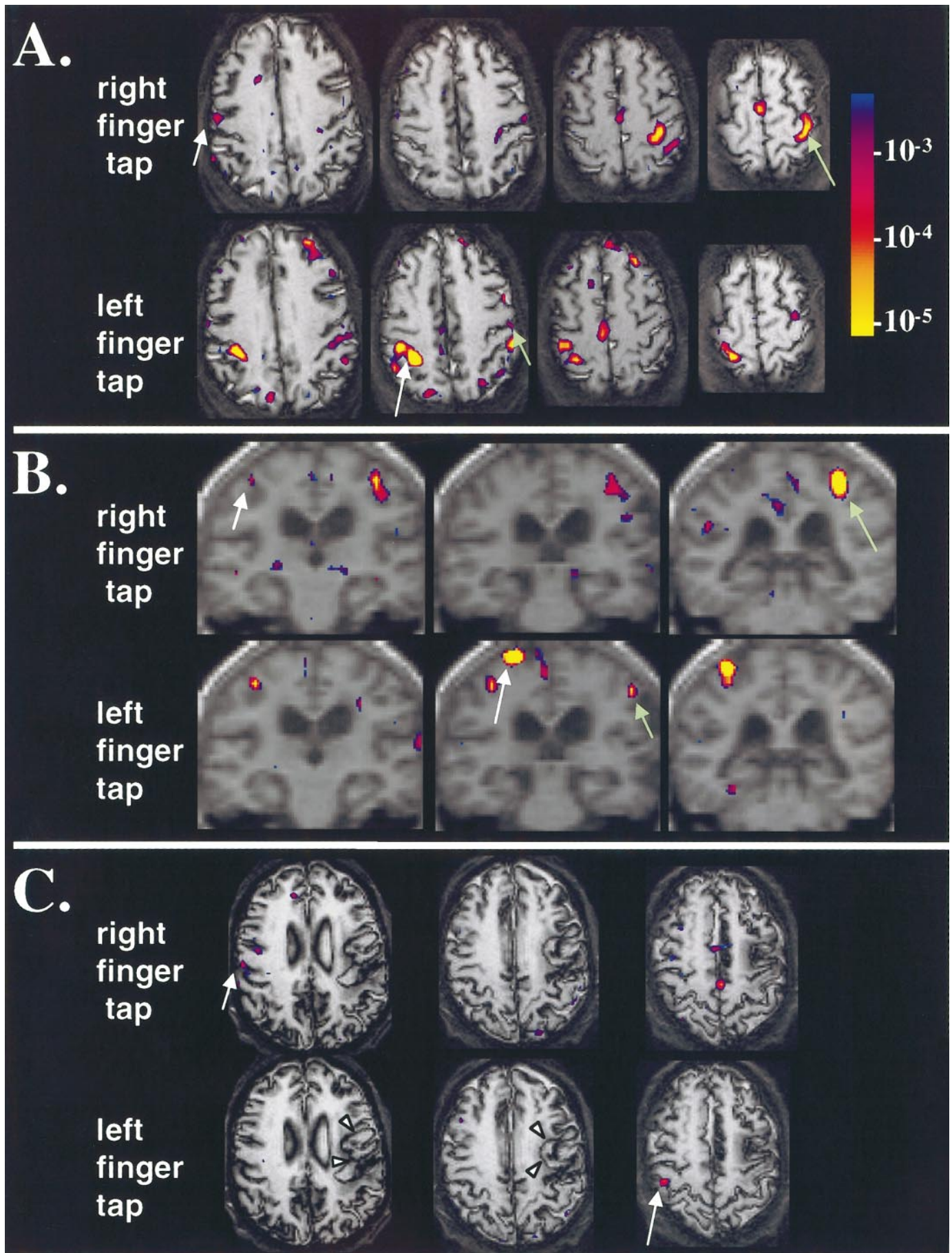
Although the magnitude of ipsilateral motor cortex activation has been carefully evaluated, the location has received little attention. In the current study, functional magnetic resonance imaging (fMRI) was used to determine the site of motor cortex activation during use of the ipsilateral hand; this was then compared with the motor cortex site identified during use of the contralateral hand.

METHODS

Twelve right-handed human subjects, five patients with good recovery after a dominant hemisphere stroke and seven age-matched controls, were imaged using a high-speed 1.5-Tesla MRI scanner after informed consent. A General Electric Signa scanner, modified by Advanced NMR Systems, and a quadrature head coil were used to obtain high-resolution gradient echo volumetric images, high-resolution echo planar anatomic images in plane with functional images, and two sets of functional images using blood oxygenation level dependent contrast. Each functional imaging set consisted of 20 contiguous axial T2*-weighted images with 7-mm thickness, 100 images/slice, 3.1-mm in-plane resolution, repetition time (TR) of 2.5 s, and echo time (TE) of 70 ms. In the first set, subjects alternated between 30-s periods of rest and 2-Hz right index finger tapping; in the second set, rest alternated with left index finger tapping. Subjects were supine in the MRI scanner, eyes closed, arms extended at the sides, and hand pronated and resting on the scanner bed. Subjects were instructed to tap the indicated index finger to a 2-Hz metronome beep presented through headphones. The cue to begin and to end finger tapping was a single light touch on the knee. Before scanning, subjects were briefly trained to follow these instructions. Accurate performance of unilateral movements was confirmed by one of the experimenters at the subject's side during imaging. During right index finger tapping, one stroke subject had very small movements of the left index finger during less than one-half the images. In addition, one control subject had occasional small movements of two fingers (right middle and right index) during the right index finger tapping task.

Image analysis was performed on Sun SPARC workstations. Head motion was corrected using image registration software (Jiang et al. 1995). For each motor task, statistical parametric maps were generated voxel-by-voxel using a *t*-test, contrasting images

The costs of publication of this article were defrayed in part by the payment of page charges. The article must therefore be hereby marked "advertisement" in accordance with 18 U.S.C. Section 1734 solely to indicate this fact.



taken during finger tapping with those taken at rest, then mildly smoothed with a Hanning filter. Significant activation was defined as pixels with $P < 0.001$. The assignment of images as rest or tapping was shifted by 5 s to account for the delay normally seen in the rise of blood flow after neuronal activation (Cohen and Bookheimer 1995). These maps were then superimposed onto the echo planar anatomic images.

For controls, both hemispheres were evaluated; for stroke subjects, only the unaffected (right) hemisphere was evaluated, because damage to the stroke-affected hemisphere could in itself alter sites of cortical activation. One control and two stroke subjects lacked significant precentral gyrus activation, leaving six control and three stroke subjects (3 male/6 female, age 69 ± 3 yr, mean \pm SE). One control had significant activation only in left precentral gyrus, leaving 14 hemispheres to be evaluated. One stroke subject had a deep stroke in the internal capsule, whereas two had a cortical stroke involving the frontal lobes.

Significantly activated pixels on the precentral gyrus were identified. The location of the precentral gyrus in the echo planar images was determined by identifying reliable sulcal landmarks (Ono et al. 1990). These landmarks were established by reviewing the high-resolution gradient echo images simultaneously reformatted in the three cardinal planes, along with a multiplanar radiological brain atlas (Damasio 1995). For example, in all hemispheres the precentral sulcus was readily identified by its junction with the superior frontal sulcus, a relationship present in 96% of hemispheres (Ono et al. 1990). Activation clusters were then identified in both hemispheres, defined as each significantly activated precentral gyrus pixel plus all contiguous significantly activated pixels. Prior human cortical mapping studies (Nii et al. 1996; Penfield and Boldrey 1937) have determined that, in many subjects, the representation for finger movements extends from precentral gyrus caudal to the central sulcus, but not rostral to the precentral sulcus. Consequently, data analysis was restricted to clusters in precentral gyrus only or in precentral plus postcentral gyri.

The single most significantly activated pixel from among these clusters was then identified in each hemisphere, for each motor task. The relationship between a given hemisphere's precentral gyrus activation sites during right and left finger tapping was explored in two ways. First, the activation sites were compared by visually inspecting the statistical parametric maps. Second, images were transformed into standard Talairach stereotaxic space (Talairach and Tournoux 1988). This transformation permitted assignment of three-dimensional coordinates for the single most significantly activated pixel and thus quantitative estimates of distances between activation foci. For each subject, the same transformation was applied to right and to left finger tapping studies. A paired t -test was used to determine whether the mean coordinates between ipsilateral and contralateral finger activation sites were significantly different. Brain activation volumes for most of the subjects have been described in a previous report (Cramer et al. 1997).

Electromyography (EMG) was used to further assess the arm intended to be at rest during each unilateral motor task. In a separate cohort of 10 normal subjects (mean age 33 ± 11 yr, 5 male/5 female, 8 right-handed/2 left-handed), EMG measurements were

made during tapping of the right index finger and during tapping of the left index finger. Nihon Kohden bioamplifiers were used with a high-pass filter of 5 Hz and a low-pass filter of 500 Hz. Bipolar surface EMG leads were placed over left trapezius, left mentalis, and bilateral flexor digitorum superficialis (FDS).

RESULTS

In the motor cortex of 11 control hemispheres, significant activation foci were identified during both ipsilateral and contralateral finger tapping and thus available for comparison. Visual inspection of the activation maps determined that the ipsilateral finger site was ventral to the contralateral finger site by a mean of 1.5 slices (7 mm thickness). The activation cluster during contralateral hand tapping was on precentral gyrus only in six hemispheres, and on precentral plus postcentral gyri in five. The activation cluster during ipsilateral hand tapping was on precentral gyrus only in eight hemispheres, and on precentral plus postcentral gyrus in three. The ipsilateral hand site's position on the gyrus, relative to the contralateral hand site, was situated more anteriorly in four hemispheres, posteriorly in three, and was approximately the same in four.

The sites of activation were compared after transformation of the images into stereotaxic space. No significant differences ($P > 0.25$, Student's t -test) in x , y , or z Talairach coordinates were found on comparing control right and left hemispheres (absolute values were used when comparing x coordinate results). The same comparisons found no differences in the mean number of millimeters separating ipsilateral and contralateral finger representation sites within each hemisphere. Results from the two hemispheres were therefore combined.

The mean Talairach coordinates [x,y,z] for the most significantly activated pixel during contralateral finger tapping [$35, -27, 55$] in the control hemispheres were each significantly different from the respective mean values during ipsilateral finger tapping [$47, -17, 44$] (see Fig. 1). The ipsilateral activation site, relative to contralateral site, was shifted laterally in 10 of 11 hemispheres (mean, 12 mm for all hemispheres, $P = 0.001$; for laterally shifted hemispheres, 13 ± 2 mm), anteriorly in 8 hemispheres (mean, 10 mm for all hemispheres, $P < 0.02$; for anteriorly shifted hemispheres, mean, 15 ± 3 mm), and ventrally in all 11 hemispheres (mean, 11 ± 3 mm, $P < 0.005$). Results in the control subject with occasional small movements of the right middle finger during right index finger tapping were concordant with the overall findings, and results remained significant when analyzed without this subject. In his left hemisphere, the ipsilateral site activated during left finger tapping

FIG. 1. Ipsilateral and contralateral hand representation sites. Green arrows, left hemisphere activations; white arrows, right hemisphere; long arrows, contralateral activations; short arrows, ipsilateral. A and C: contiguous axial slices are arranged with images at left ventral to those at right. B: 3-mm-thick coronally reconstructed slices are arranged with images at left anterior to those at right; there is a 3-mm gap between slices. The color bar at right codes the P value for each pixel showing significant activation in relation to motor task performance. A and B: in each hemisphere of these control subjects, the site of motor cortex activation during tapping of the ipsilateral finger is lateral, anterior, and ventral to the site seen during tapping of the contralateral finger. Within each hemisphere of subject A, both the ipsilateral and the contralateral finger representation sites were simultaneously activated during tapping of the finger contralateral to that hemisphere, suggesting that the ipsilateral finger site relates to bilateral hand movements. C: a stroke patient with excellent recovery 14 mo after a left frontoparietotemporal cortical embolus. Arrowheads indicate the infarct location. In the unaffected right hemisphere, the activation site seen during right (recovered) finger tapping is lateral, anterior, and ventral to the activation site seen during left finger tapping.

was located 6 mm lateral, 8 mm anterior, and 8 mm ventral as compared with the contralateral site activated during right finger tapping.

A similar shift in the ipsilateral activation site was observed in the unaffected hemisphere of all three stroke patients. The ipsilateral site was lateral (mean, 17 mm), anterior (mean, 11 mm), and ventral (mean, 28 mm) compared with the site activated during contralateral finger tapping. Results in the stroke patient with trace movements of the left index finger during tapping by the right index finger were consistent with the findings in control subjects. In this stroke patient's unaffected hemisphere, the ipsilateral site was shifted 14 mm lateral, 6 mm anterior, and 10 mm ventral compared with the contralateral activation site.

To explore a possible role for homotopic callosal connections, comparison was made of the ipsilateral activation site generated in one hemisphere and the contralateral activation site generated simultaneously in the other hemisphere. In the 11 control hemispheres, the ipsilateral site was shifted laterally in all 11 (mean, 12 mm, $P < 0.005$), anteriorly in 9/11 hemispheres (mean, 10 mm for all hemispheres, $P < 0.03$), and ventrally in 8/11 hemispheres (mean, 11 mm for all hemispheres, $P < 0.02$).

The activation clusters related to ipsilateral and to contralateral finger movement overlapped in 3 of the 11 control hemispheres. Furthermore, in these three plus three other control hemispheres, both the ipsilateral and the contralateral finger representation sites were simultaneously activated within the hemisphere contralateral to the tapping finger (for example, see *subject A* in Fig. 1).

In the EMG studies, activity in excess of 100 μV was easily measured over each muscle during its intended contraction. In all 10 cases, the 3 left-sided muscles remained silent during right index finger tapping. During left index finger tapping, right FDS, left trapezius, and left mentalis remained silent.

DISCUSSION

The results of the current study suggest that activation of motor cortex during ipsilateral hand movements occurs at a site distinct from the region of motor cortex related to contralateral hand movements. This difference was significant in all three planes. Results obtained by visual inspection of the activation maps were in general agreement with those obtained after stereotaxic transformation.

Previous studies have suggested that ipsilateral hand movements activate a separate region of motor cortex compared with contralateral hand. Bucy and Fulton (1933), using cortical stimulation in monkeys, identified an area anterior to the contralateral representation site that was associated with bilateral extremity movements. Lesion studies in monkeys have demonstrated that the corticospinal efferents with greater projection to ipsilateral spinal cord arise from more anterior aspects of the precentral gyrus (Kuypers and Brinkman 1970). Aizawa et al. (1990), using cortical microstimulation in one monkey as well as recording from a second monkey, found that ipsilateral and bilateral hand muscle representations on precentral gyrus were anterolateral to the region associated with contralateral hand muscle representations. Wassermann et al. (1994), using transcranial magnetic

stimulation in humans, found that in two of six subjects, the largest motor-evoked potentials in an ipsilateral finger muscle occurred with stimulation of a motor cortex area lateral to the contralateral finger representation site. The current results, obtained with the use of fMRI, are concordant with these prior studies and extend these findings to a larger number of human subjects.

Multiple foci related to finger musculature have previously been described in primate motor cortex, but the relationship of the different foci to ipsilateral or bilateral movement was not formally evaluated in these studies (Sanes et al. 1995; Sato and Tanji 1989; Sessle and Wiesendanger 1982). Two spatially separate upper extremity representation sites identified in primary motor cortex did not show differences in output, as assessed with the use of intracortical stimulation (Strick and Preston 1982) and tracing (He et al. 1993) methods. In humans, two divisions of primary motor cortex with distinct histological and sensory properties have been demonstrated, but no relationship of these areas to the ipsilateral muscles was described (Geyer et al. 1996).

Hand representation sites in primate motor cortex have callosal connections (Gould et al. 1986), suggesting that ipsilateral activation might arise from a transcallosal signal generated in the homotopic contralateral activation site. This hypothesis was tested by comparing the locations of activation sites simultaneously generated in the right and left hemispheres of control subjects. The ipsilateral hand site in one hemisphere was found to be lateral, anterior, and ventral relative to the contralateral hand site simultaneously activated in the other hemisphere. The site of motor cortex activation during use of the ipsilateral hand is thus similarly shifted relative to either hemisphere's contralateral hand activation site. Ipsilateral activation could conceivably arise from nonhomotopic callosal signals, but the finding that bilateral motor cortices are activated at approximately the same time before movement (Hoshiyama et al. 1997) lends support to the conclusion that ipsilateral activation does not arise as a consequence of contralateral activation.

The role of the ipsilateral activation site in finger movements remains to be clarified. In humans, cortical potentials can be simultaneously detected in bilateral motor cortex before performance of a unilateral motor task (Hoshiyama et al. 1997), suggesting a contribution to movement preparation. Both intracortical stimulation and single-cell recording studies in motor cortex of monkeys have identified neurons with activity related to ipsilateral hand movements (Aizawa et al. 1990; Tanji et al. 1988). Transcranial magnetic stimulation of motor cortex interferes with ipsilateral performance of simple and complex movements by either hand (Chen et al. 1997). Also, ~15% of corticospinal tract fibers reach spinal gray matter undecussated (Nyberg-Hansen and Rinvik 1963), suggesting a direct contribution to the genesis of movement. Increased ipsilateral motor cortex activation has been described in relation to movement complexity (Rao et al. 1993; Salmelin et al. 1995). In this regard, although ipsilateral activation was restricted to precentral gyrus in most of the hemispheres studied, this site might nevertheless be Brodmann area 6, or premotor cortex, in light of its ventral position. Rostral motor cortex receives proprioceptive input (Evarts and Fromm 1981), suggesting a possible role in postmovement sensory processing. Further studies using

methods with finer temporal resolution may be of value in exploring these possible roles for the described site.

In most normal controls and patients with good recovery after stroke, unilateral finger movements activate a hand representation site in the ipsilateral motor cortex, with activation being larger in the latter population (Cao et al. 1998; Chollet et al. 1991; Cramer et al. 1997; Weiller et al. 1993). Visual observation and EMG evaluation confirm that this cortical activation is not related to muscle activity in the arm intended to be at rest, in the trapezius, or in the face. Activation of the ipsilateral hand site during use of either hand suggests that, in some hemispheres, this site may relate to bilateral hand movements. Further characterization of the ipsilateral hand site and its efferent pathways may be of value in the design of treatments targeting stroke recovery.

S. C. Cramer was supported by a grant from the National Stroke Association.

Present address and address for reprint requests: S. C. Cramer, Dept. of Neurology, University of Washington, 1959 NE Pacific, Rm. RR650, Box 356465, Seattle, WA 98195-6465.

Received 6 July 1998; accepted in final form 18 September 1998.

REFERENCES

AIZAWA, H., MUSHIAKE, H., INASE, M., AND TANJI, J. An output zone of the monkey primary motor cortex specialized for bilateral hand movement. *Exp. Brain Res.* 82: 219–221, 1990.

BUCY, P. AND FULTON, J. Ipsilateral representation in the motor and premotor cortex of monkeys. *Brain* 56: 318–342, 1933.

CAO, Y., D'OLHABERRIAGUE, L., VIKINGSTAD, E., LEVINE, S., AND WELCH, K. Pilot study of functional MRI to assess cerebral activation of motor function after poststroke hemiparesis. *Stroke* 29: 112–122, 1998.

CHEN, R., COHEN, L. G., AND HALLETT, M. Role of the ipsilateral motor cortex in voluntary movement. *Can. J. Neurol. Sci.* 24: 284–291, 1997.

CHOLLET, F., DIPIERO, V., WISE, R., BROOKS, D., DOLAN, R., AND FRACKOWIAK, R. The functional anatomy of motor recovery after stroke in humans: a study with positron emission tomography. *Ann. Neurol.* 29: 63–71, 1991.

COHEN, M. AND BOOKHEIMER, S. Localization of brain function using magnetic resonance imaging. *Trends Neurosci.* 17: 268–277, 1995.

CRAMER, S., NELLES, G., BENSON, R., KAPLAN, J., PARKER, R., KWONG, K., KENNEDY, D., FINKLESTEIN, S., AND ROSEN, B. A functional MRI study of subjects recovered from hemiparetic stroke. *Stroke* 28: 2518–2527, 1997.

DAMASIO, H. *Human Brain Anatomy in Computerized Images*. New York: Oxford Univ. Press, 1995.

DETTMERS, C., FINK, G., LEMON, R., STEPHAN, K., PASSINGHAM, R., SILBERSWEIG, D., HOLMES, A., RIDDING, M., BROOKS, D., AND FRACKOWIAK, R. Relation between cerebral activity and force in the motor areas of the human brain. *J. Neurophysiol.* 74: 802–815, 1995.

EVARTS, E. V. AND FROMM, C. Transcortical reflexes and servo control of movement. *Can. J. Physiol. Pharmacol.* 59: 757–775, 1981.

GEYER, S., LEDBERG, A., SCHLEICHER, A., KINOMURA, S., SCHORMANN, T., BURGEL, U., KLINGBERG, T., LARSSON, J., ZILLES, K., AND ROLAND, P. Two different areas within the primary motor cortex of man. *Nature* 382: 805–807, 1996.

GOULD, H., CUSICK, C., PONS, T., AND KAAS, J. The relationship of corpus callosum connections to electrical stimulation maps of motor, supplementary motor, and the frontal eye fields in owl monkeys. *J. Comp. Neurol.* 247: 287–325, 1986.

HE, S., DUM, R., AND STRICK, P. Topographic organization of corticospinal projections from the frontal lobe: motor areas on the lateral surface of the hemisphere. *J. Neurosci.* 13: 952–980, 1993.

HOSHIYAMA, M., KAKIGI, R., BERG, P., KOYAMA, S., KITAMURA, Y., SHIMOJO, M., WATANABE, S., AND NAKAMURA, A. Identification of motor and sensory brain activities during unilateral finger movement: spatiotemporal source analysis of movement-associated magnetic fields. *Exp. Brain Res.* 115: 6–14, 1997.

JIANG, A., KENNEDY, D., JR., B., WEISSKOFF, R., TOOTELL, R., WOODS, R., BENSON, R., KWONG, K., BRADY, T., ROSEN, B., AND BELLIVEAU, J. Motion detection and correction in functional MR imaging. *Hum. Brain Map.* 3: 224–235, 1995.

KIM, S.-G., ASHE, J., GEORGOPOULOS, A., MERKLE, H., ELLERMANN, J., MENON, R., OGAWA, S., AND UGURBIL, K. Functional imaging of human motor cortex at high magnetic field. *J. Neurophysiol.* 69: 297–302, 1993.

KUYPERS, H. AND BRINKMAN, J. Precentral projections to different parts of the spinal intermediate zone in the rhesus monkey. *Brain Res.* 24: 29–48, 1970.

MAKI, A., YAMASHITA, Y., WATANABE, E., AND KOIZUMI, H. Visualizing human motor activity by using non-invasive optical topography. *Front. Med. Biol. Eng.* 7: 285–297, 1996.

MATTAY, V., CALLICOTT, J., BERTOLINO, A., SANTHA, A., TALLENT, K., GOLDBERG, T., FRANK, J., AND WEINBERGER, D. Abnormal functional lateralization of the sensorimotor cortex in patients with schizophrenia. *Neuroreport* 8: 2977–2984, 1997.

MULLER, K., KASS-ILYYA, F., AND REITZ, M. Ontogeny of ipsilateral corticospinal projections: a developmental study with transcranial magnetic stimulation. *Ann. Neurol.* 42: 705–711, 1997.

NII, Y., UEMATSU, S., LESSER, R., AND GORDON, B. Does the central sulcus divide motor and sensory functions? Cortical mapping of human hand areas as revealed by electrical stimulation through subdural grid electrodes. *Neurology* 46: 360–367, 1996.

NYBERG-HANSEN, R. AND RINVIK, E. Some comments on the pyramidal tract, with special reference to its individual variations in man. *Acta Neurol. Scand.* 39: 1–30, 1963.

ONO, M., KUBIK, S., AND ABERNATHEY, C. *Atlas of the Cerebral Sulci*. Stuttgart, Germany: Thieme, 1990.

PENFIELD, W. AND BOLDREY, E. Somatic motor and sensory representation in the cerebral cortex of man as studied by electrical stimulation. *Brain* 60: 389–443, 1937.

RAO, S., BINDER, J., BANDETTINI, P., HAMMEKE, T., YETKIN, F., JESMANOWICZ, A., LISK, L., MORRIS, G., MUELLER, W., ESTKOWSKI, L., WONG, E., HAUGHTON, V., AND HYDE, J. Functional magnetic resonance imaging of complex human movements. *Neurology* 43: 2311–2318, 1993.

SALMELIN, R., FORSS, N., KNUUTILA, J., AND HARI, R. Bilateral activation of the human somatomotor cortex by distal hand movements. *Electroencephalogr. Clin. Neurophysiol.* 95: 444–452, 1995.

SANES, J., DONOGHUE, J., THANGARAJ, V., EDELMAN, R., AND WARACH, S. Shared neural substrates controlling hand movements in human motor cortex. *Science* 268: 1775–1777, 1995.

SATO, K. AND TANJI, J. Digit-muscle responses evoked from multiple intracortical foci in monkey precentral motor cortex. *J. Neurophysiol.* 62: 959–970, 1989.

SESSLE, B. AND WIESENDANGER, M. Structural and functional definition of the motor cortex in the monkey (*macaca fascicularis*). *J. Physiol. (Lond.)* 323: 245–265, 1982.

SHIBASAKI, H. AND KATO, M. Movement-associated cortical potentials with unilateral and bilateral simultaneous hand movement. *J. Neurol.* 208: 191–199, 1975.

STRICK, P. AND PRESTON, J. Two representations of the hand in area 4 of a primate. I. Motor output organization. *J. Neurophysiol.* 48: 139–149, 1982.

TALAIRACH, J. AND TOURNOUX, P. *Co-Planar Stereotaxic Atlas of the Brain*. New York: Thieme, 1988.

TANJI, J., OKANO, K., AND SATO, K. Neuronal activity in cortical motor areas related to ipsilateral, contralateral, and bilateral digit movements of the monkey. *J. Neurophysiol.* 60: 325–343, 1988.

WASSERMANN, E., PASCUAL-LEONE, A., AND HALLETT, M. Cortical motor representation of the ipsilateral hand and arm. *Exp. Brain Res.* 100: 121–132, 1994.

WEILLER, C., RAMSAY, S., WISE, R., FRISTON, K., AND FRACKOWIAK, R. Individual patterns of functional reorganization in the human cerebral cortex after capsular infarction. *Ann. Neurol.* 33: 181–189, 1993.